

Optimal post-breeding interval for pregnancy diagnosis in mares by using ultrasonographic technique

Omran, S. N.¹ and Rasheed Y. M.²@

1. Department of Surgery and Obstetrics, College of Veterinary Medicine, Baghdad University

2. Department of Anatomy and Histology, College of Veterinary Medicine, Diyala University, Iraq

E-Mail: yassin_vet@yahoo.com

Accepted on: 7/1/2013

Summary

The present study was conducted in two different farms, including (256) foaling mares in : AL-Laith equine herd and equestrian club in AL-Ameria, 4-14 years old foaling mares which are situated in areas around Baghdad and extended one calendar from July 2011 until July 2012 . These mares were examined for pregnancy diagnosis by trans-rectal ultrasonography using a 5 MHz linear-array transducer between Days 10 and 40 after breeding (breeding day = Day 0). Criteria to assess the accuracy of trans-rectal sonography were overall accuracy (correct diagnoses/all diagnoses), sensitivity (correct diagnoses "pregnant"/all pregnant animals), and specificity (correct diagnoses "non-pregnant" /all non-pregnant animals). The sensitivity, specificity and accuracy of trans-rectal ultrasonography were 91.4%, 96.2% and 94.7%, respectively, around day (10-40). Accuracy, Sensitivity and Specificity of pregnancy diagnosis were superior (97.8%, 95.2% and 100%), respectively, in (31 - 35) day post breeding ($P < 0.01$). The results of this study showed a significant difference ($P < 0.01$) in the parameters of sensitivity and various post-breeding intervals. The results of the present study revealed that using trans-rectal ultrasound for pregnancy diagnosis in mares could be used and are reliable under field conditions from day (31) of Gestation onward.

Keywords: Pregnancy diagnosis, Mare, Ultrasound.

Introduction

It is important to be able to tell if a mare is pregnant for management and husbandry reasons (1). In general, linear-array, real-time, B-mode ultrasound scanners are best suited for veterinary applications involving early pregnancy diagnosis in mares. In addition, the ability to accurately detect pregnancy during the early intra-uterine period has also been critical in the development of techniques to successfully manage twin pregnancy and for detecting abnormal conceptus development, pregnancy loss or threatened pregnancy loss (2). Real-time ultrasonic imaging provides a noninvasive technique to image directly, in situ, the internal and external anatomy of reproductive organs and tissues, and to characterize reproductive events (e.g., ovulation, transition of the uterus from a diestrous to an estrous echotexture) (3 and 4).

Ultrasonography has proved its worth in improving the efficiency of recent gynecological technique like artificial insemination and embryo transfer. There is still a great potential for the continued application of this technology to further improve our understanding of the reproductive processes,

disease diagnosis and to maximize reproductive efficiency of the mare(5).

The area that has arguably benefited more from the development of ultrasound technology than any other area is reproduction in large animals. In many cases, rectal palpation has been replaced by trans-rectal ultrasonography for pregnancy determination, and diagnoses associated with uterine and ovarian infections (6). More accurate measurements of the reproductive organs has opened doors to new areas of research and validated or refuted data from past reports. The aims of this study were to evaluate the use of the real time ultrasonography (RTU) on the pregnancy diagnosis at (10-40) days post-breeding and to determine the effect of the time taken for the pregnancy diagnosis on the sensitivity, specificity and accuracy of the diagnosis.

Materials and Methods

Two hundred and fifty seven mares are employed in this study. They were from different farms, including: AL-Laith equine herd (115 mares) and equestrian club in AL-Ameria (142 mares). These mares were from different breeds (Arabian, Thoroughbred and

Cross breed), and aged from (4-14) years which was estimated by dentation.

Ultrasound examinations were done weekly, with a real time B-Mode scanner equipped with a 5MHz linear array rectal transducer. There were two type of the scanner used :(1) (SIUI-CTV-200V), China. (2) Pie Medica (scanner 480), made in Netherlands 2001.

The examination was carried out at various post-breeding intervals (Table, 1) and the ultrasonographic examination was made according to (7).

Table, 1: Post-breeding examinations and numbers of ultrasonic scanning's.

Post-breeding interval(day)	Total examinations
10-----15	460
16-----20	265
21-----25	140
26-----30	60
31-----35	47
36-----40	33

The Statistical Analysis System- SAS (8) was used to find the effect of different factors in studied parameters (percentage). The Qi-square (χ^2) test at the comparative between percentages in this study on 0.01 or 0.05 level of probability. To estimate the competence of ultrasoni examination in pregnancy diagnosis we used the fallowing formula which clarify according to researchers (9 and 10). The sensitivity was defined as the number of pregnant females diagnosed correctly/total number of females diagnosed as pregnant. The specificity as the number of non-pregnant females diagnosed correctly/total number of females diagnosed as non-pregnant. The accuracy was defined as the number of females diagnosed correctly (either pregnant or non-pregnant)/ total females diagnosed.

$$\text{Sensitivity (Se.)} = \frac{TP}{(TP + FN)} \times 100$$

$$\text{Specificity (Sp.)} = \frac{TN}{(TN + FP)} \times 100$$

$$\text{Accuracy} = \frac{TP + TN}{(TP + TN + FP + FN)} \times 100$$

Whereas:-

- True Positive (Pregnant).
- False Negative (Pregnant).
- True Negative (Note Pregnant).
- False Positive (Note Pregnant).

Results and Discussion

The results of our study as shown in (Table, 2) revealed that there were a relationship between each of the specificity, sensitivity, accuracy and the post breeding interval examination (breeding Day =Day 0) in the diagnosis of pregnancy in mares using a technique of ultrasound scanning. Where the percentage of each of the specificity sensitivity and accuracy as follows 96.2%, 91.4% and 94.7% respectively on the days (10-40) after breeding.

Table, 2: Effect of post-breeding interval on Specificity, Sensitivity and Accuracy of pregnancy diagnosis.

Post-breeding interval(day)	Total exam.	Specifi city (%)	Sensiti vity (%)	Accuracy (%)
10-----15	460	97.4	79.7	92.5
16-----20	265	98.1	93.6	96.4
21-----25	140	97.4	92.8	95.5
26-----30	60	93.3	92.3	92.8
31-----35	47	100	95.2	97.8
36-----40	33	90.9	95	93.5
10-----40	1005	96.2	91.4	94.7
Qi-square - χ^2	---	2.734 NS	6.829 **	2.177 NS

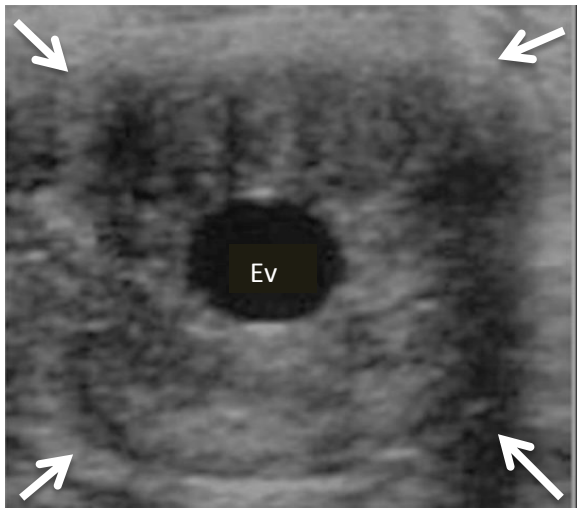
NS: non-significant.

** (P<0.01).

Statistical analysis of the result exhibited that there were significant differences (P<0.01) between post-breeding interval (10-40) days and Sensitivity .The optimal post-breeding time for pregnancy diagnosis by using Trans-rectal ultrasonic method was (31-35) days and the specificity, sensitivity and accuracy were 100%, 95.2% and 97.8% respectively. These results could be explained according to use of ultrasonic device specifications capable of diagnosing of early pregnancy with high accurately and because of the earlier sonographic indications of pregnancy are not sufficiently reliable for large scale accurate pregnancy diagnosis (11).

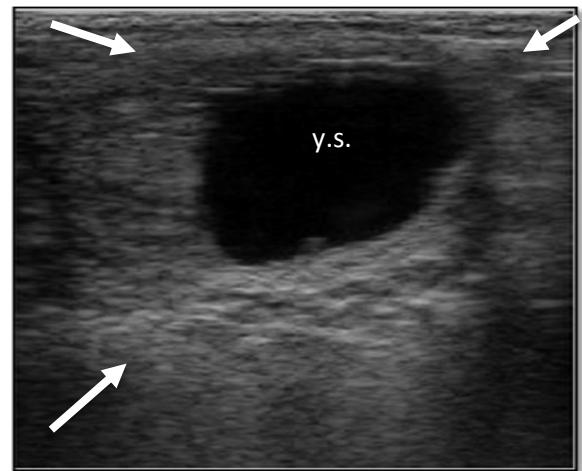
The sensitivity of pregnancy detection (table 2) at around (10-15) day post-breeding was 79.7%, this findings close to result of England

(12) who reported that the sensitivity of no more than 70% on day (10th) after ovulation, the consequence of both studies is due to increment numbers of false negative at this period due to mobility of embryonic vesicle at this stage as well as a tiny of embryonic vesicle (2-3) mm (13) (Fig. 1).



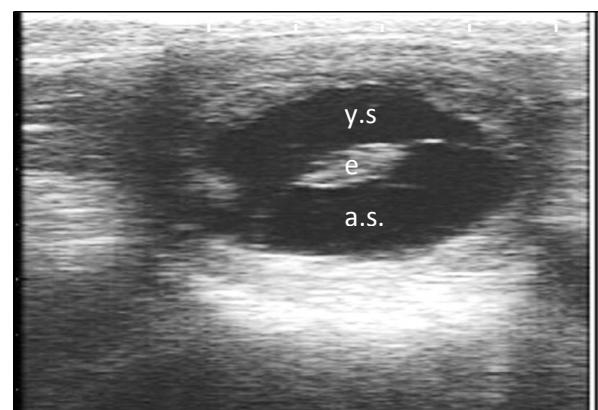
Figure, 1: Ultrasonic image of conceptus on Day (14). Embryonic vesicle (Ev). Periphery of cross-section of the uterine horn (arrows).

The sensitivity of Trans-rectal ultrasound examination in this study between (21-25) days after breeding (Fig. 2), was 92.8%. This finding disagree with (14 - 16) in cattle and buffalo, whose described that the sensitivity were reached to 44.8%, 74.5% and 44.4%, respectively. The decline of sensitivity in previous studies compared to the present study may be due to the increase numbers of animals which diagnosed as false negative that attributed to the apprentice examiner or to the species of animal which exploit in previous studies. Meanwhile, other researcher (17 -19) who reported that the most appropriate time for pregnancy diagnosis using ultrasonography with high accuracy in cattle and buffaloes appears to be at day (28-30) using a trans-rectal linear array probe of 5.0 to 7.5 MHz frequencies. The sensitivity of ultrasound scanning in this study and previous studies, mentioned above, were convergent results around (31-35) days post-breeding interval, 95.2%, 97.7%, 100% and 100%, respectively.



Figure, 2: Ultrasonic images of conceptus at day 21. Yolk sac (y.s). Embryo proper at 6 o'clock (echoic projection). The disproportional hypertrophy of the endometrial folds, the outer limits of the uterine wall is delineated by arrows.

While Specificity of ultrasound scanning amounted in the current study between (26-30) days after breeding (Fig. 3) approximate to 93.3%, and this result consistent with the consequence of previous researchers (15 and 16) as were 96.6%, 96.2%, respectively. Pieterse *et al.* (14) advert to the low specificity of pregnancy diagnosis in the identical period attain 87.8%, and attributed this decline to the rise in false positive of pregnancy diagnosis in this period or due to use of ultrasonic machine less specifications of equipment used in other studies. Indeed, the specificity of the method in recognizing non-pregnancy animals is very high if the operator is adequately experienced (20).



Figure, 3: Ultrasonic image of conceptus at 30 day .yolk sac (y.s),allantoic sac(a.s),Embryo (e).

The results of the current study indicated that the accuracy of ultrasound through the period 31-35 days post-breeding were higher values reaching 97.8% (Table, 2). This

observation disagree with the results of (21 and 22) who mentioned that the accuracy of trans-rectal ultrasound examination reached 99% and 100%, respectively, during the period of 10 -15 days of gestation. The accuracy of examination in the current study, during the period 10-15 days post breeding, was approximating to result of (23) which were 92.5% and 95%, respectively. Accuracy of ultrasound examination of the present study was approximating the findings of the study conducted on the cows (24), which were 95.5% and 100%, respectively, during the period of gestation 21-25 days. Meanwhile, Reef, (6) reported that image is possible to be affected by the type of device, therefore, the early stages of pregnancy diagnosis could be of high accuracy when the transducer frequencies available is high. The low accuracy of trans-rectal ultrasonic in this current study compared to other studies, may be due to the increase cases of early embryonic loss during this period (25).

References

1. Pycock, J.F. (2007). Pregnant Diagnosis in the Mare. In: Current Therapy in Equine Reproduction. Samper, J.C.; Pycock, J.F. and McKinnon, A. O. (ed). Saunders Elsevier, PP:335-342.
2. Stout, T.A.E. (2009). The early pregnancy .In: Equine breeding management and artificial insemination. Samper, J.C. (ed.). . Saunders Elsevier.2nd ed. PP:223-239.
3. Griffin, P.G. and Ginther, O.J. (1992). Research applications of ultrasonic imaging in reproductive biology. J. of Anim. Sci., 70(3):953-972.
4. Boyd, J. S. and Omran, S. N. (1991). Diagnostic ultrasonography of the bovine female reproductive tract. In Practice, 13(3):109-118.
5. Medan, M.S. and Abd El-Aty, A.M. (2010). Advances in ultrasonography and its applications in domestic ruminants and other farm animals reproduction. J. Advanced Res., 1(2):123-128.
6. Reef, V.B. (1991). The use of diagnostic ultrasound in the horse. Ultrasound Quarterly, 9 (1): 1-34.
7. Sertich, P.L. (2007). Pregnancy evaluation in the mare. In: Current therapy in large animal Theriogenology. Youngquist, R.S. and Threlfall, W.R. (Ed.). Saunders Elsevier. 2nd ed. PP :99-106.
8. SAS (2004). SAS/STAT User's Guide for personal computers. Release 7th ed. O.SAS. Institute Inc., Cary. NC. USA. (SAS: Statistical Analysis System).
9. Kahn,W.; Achtzehn, J.; Kahn, B.; Richter, A.; Schulz, J. and Wolf, M. (1993). Sonography of pregnancy in sheep. II. Accuracy transrectal and transcutaneous pregnancy diagnosis .Dtsch Tierarztl Wochenschr, 100(1):29-31.
10. Williams, S.I.; Pineyro, P. and Sota, R.L. (2008). Accuracy of pregnancy diagnosis in swine by ultrasonography. Can. Vet. J., 49 (3):269-273.
11. Kahn, W. (1992). Ultrasonography as a diagnostic tool in female animal reproduction. Animal Rep. Sci., 28(1-4):1-10.
12. England, G. (1994). Real-time ultrasonography for the diagnosis and management of equine pregnancy. J. B. Vet. Assoc., 16:84-92.
13. Leith, G.S. and Ginther, O.J. (1984). Characterization of intrauterine mobility of the early equine conceptus. Theriogeno., 22(4):401-408.
14. Pieterse, M.C.; Szenci, O.; Willemse; A.H.; Bajcsy, C.S.; Dielemen, S.J. and Taverne, M.A. (1990). Early pregnancy diagnosis in cattle by means of linear-array real-time ultrasound scanning of the uterus and a qualitative and quantitative milk progesterone test. Theriogeno., 33(3):697-707.
15. Romano, J.E.; Thompson, J.A.; Forrest, D.W.; Westhusin, M.E.; Tomaszewski, M.A. and Kraemer, D.C. (2006). Early pregnancy diagnosis by trans-rectal ultrasonography in dairy cattle. Theriogeno., 66(4):1034-1041.
16. Karen, A.; Darwish, S.; Ramoun, A.; Tawfeek, K.; VanHanh, N.; Sousa, N.M.; Sulon, J.; Szenci, O. and Beckers, J.F. (2007). Accuracy of ultrasonography and pregnancy-associated glycoprotein test for pregnancy diagnosis in buffaloes. Theriogeno., 68(8):1150-1155.

17. Ali, A. and Fahmy, S. (2008). Ultrasonographic fetometry and determination fetal sex in buffaloes (*Bubalus bubalis*). *Animal Reprod.Sc.*, 106:90-99.
18. Kahn, W.; Fraunholz, J.; Kaspar, B. and Pyczak, T.(1990). Sonographic diagnosis of early pregnancy in horses, cattle, sheep, goats, swine, dogs and cats. Standard values and limitations. *Berl. Munch Tierarztl Wochenschr.* 103(6):206-211.
19. Belluzzi, S.; Mari, G. and Petrobelli, F. (2000). Transrectal ultrasonography for pregnancy diagnosis and foetal sex determination in bovine reproduction. *Atti della Societa' Italiana di Buiatria*, 32:187-192.
20. Gearhart, M.A.; Wingfield, W.E.; Knight, A.P.; Smith, J.A.; Dargatz, D.A. ;Boon, J.A. and Stokes ,C.A . (1988) .Real-time ultrasonography for determining pregnancy status and viable fetal numbers in ewes. *Theriogeno.*, 30(2):323-337.
21. Couto, G.B.; Lefebvre, R.C.; Grand,F.X. and Raggio, I. (2011). Section 2 Pregnancy Diagnosis up to 60 Days. In: *Clinical Veterinary Advisor: THE HORSE* .Wilson, D.A. (ed.).Saunders. PP:809-810.
22. Kamble, P.C.; Birade, H.S.; Deopurkar, V.L.; Patil, M.B.; Bakshi, S.A.; Chinchkar, S.R.; Gulavane, S.U. and Dagli, N.R. (2005). Early pregnancy diagnosis by ultrasonography in thoroughbred mares. *J. of Bombay Vet. College*, 13(1-2):33-35.
23. Chevalier, F. and Palmer, E. (1982). Ultrasonic echography in the mare. *J. Reprod. Fertil. Suppl.*, 32:423-430.
24. Kastelic, J.P.; Curran, S. and Ginther, O.J. (1989). Accuracy of ultrasonography for pregnancy diagnosis on days 10 to 22 in heifers. *Theriogenology*, 31(4):813-820.
25. Villahoz, M.D.; Squires, E.L.; Voss, J.L. and Shideler, R.K. (1985). Some observation on early embryonic death in mares. *Theriogenology*, 23(6):915-924.

الوقت الأمثل لتشخيص الحمل بعد التسفيد في الأفراس باستخدام تقنية الموجات صوتية

سليم نجم عمران¹ وياسين محمود رشيد²

¹ فرع الجراحة والتوليد- كلية الطب البيطري- جامعة بغداد². فرع التشريح والانسجه- كلية الطب البيطري- جامعة ديالى - العراق

الخلاصة

أجريت الدراسة الحالية في نادي الفروسية ومزرعة الليث لتربية الخيول والواقعتان في اطراف بغداد، إذ ضمت الدراسة 257 فرسا تراوحت اعمارها من 4-14 سنة. وامتدت الدراسة لمدة عام بدءا من تموز 2011 ولغايه تموز 2012. استخدمت تقنية الموجات صوتية مع مجس مستقيمي ذو تردد 5 ميغاهرتز لتشخيص الحمل المبكر في الأفراس خلال 10 الى 40 يوما بعد التسفيد، واعتبر يوم التسفيد هو يوم الصفر. وكانت معايير صحة التشخيص باستخدام هذه التقنيه هي الدقة الكلية (التشخيص الصحيح " حامل + غير الحامل" / جميع التشخيصات)، الحساسية (التشخيص الصحيح " حامل" / جميع الحيوانات الحوامل)، والنوعية (التشخيص الصحيح " غير الحوامل" / جميع الحيوانات غير الحوامل). إذ كانت الحساسية، الخصوصيه ودقة الفحص بالموجات صوتية عبر المستقيم، 91.4%، 96.2% و 94.7%، على التوالي، خلال (10-40) يوم بعد التسفيد. وبلغت نسبة الدقة، الحساسية والنوعية أعلى قيمة لها (97.8%، 95.2%، 100%) على التوالي، في مرحلة الحمل 31 إلى 35 يوما ($P < 0.01$). وأظهرت النتائج وجود فرق معنوي بين حساسيه الفحص وبين فترات الحمل المختلفه. كما بينت الدراسة أن تقييم الحمل في الأفراس باستخدام تقنية الموجات صوتية عبر المستقيم تعد طريقة موثوقة وسريعة وملائمة للظروف الحقلية خلال (31) يوم من الحمل ولغاية نهاية مدة الحمل.

الكلمات المفتاحية: تشخيص الحمل ، الأفراس ، الموجات صوتية .